

# Nephroquiz 1: Cyclophosphamide or Mycophenolate Mofetil?

Fariba Samadian,<sup>1</sup> Mahmoud Parvin,<sup>2</sup> Amirhossein Faraji,<sup>1</sup>  
Pedram Ahmadpoor<sup>1</sup>

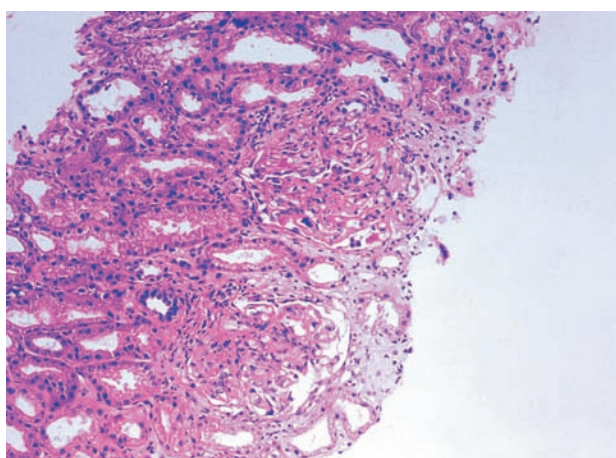
IJKD 2009;3:112-3  
www.ijkd.org

<sup>1</sup>Division of Nephrology,  
Department of Medicine,  
Shahid Labbafinejad Medical  
Center, Shahid Beheshti  
University of Medical Sciences,  
Tehran, Iran

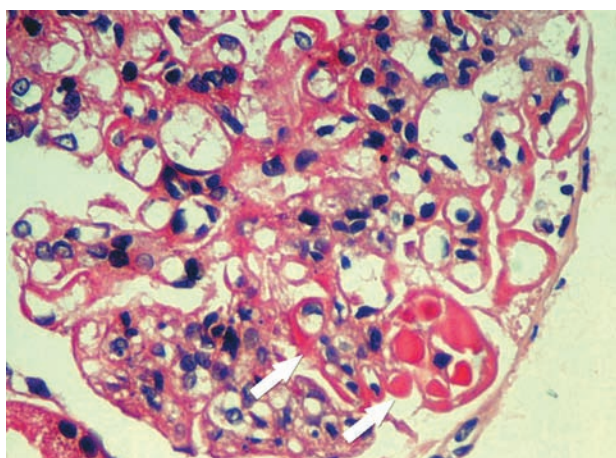
<sup>2</sup>Department of Pathology,  
Shahid Labbafinejad Medical  
Center, Shahid Beheshti  
University of Medical Sciences,  
Tehran, Iran

## CASE

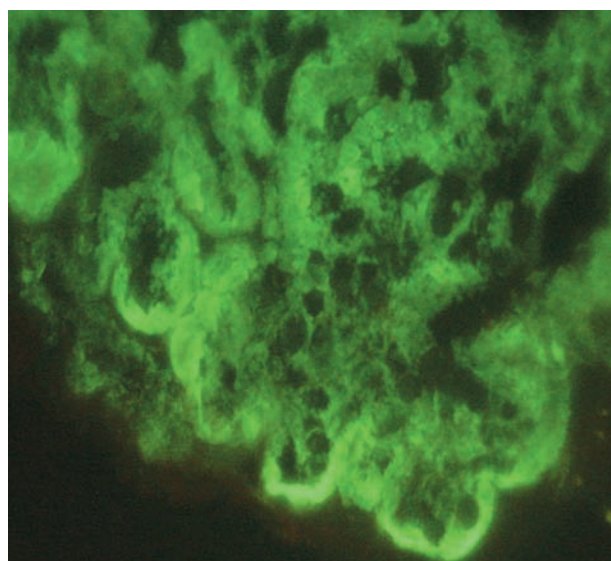
A 36-year-old man was admitted because of weakness, generalized edema, skin rash, and acute kidney failure with active urine sediment. Results of laboratory studies were as follows: blood leukocyte count,  $14 \times 10^9/L$ ; hemoglobin, 10 g/dL; blood platelet count,  $145 \times 10^9/L$ ; blood urea nitrogen, 102 mg/dL; serum creatinine, 5.8 mg/dL; complement 3, 32 mg/dL; complement 4, 3 mg/dL; serum hemolytic activity (CH50), 100 U/mL; antinuclear antibody, 1/80; and anti-double-stranded-DNA, 1/20. On pathologic examination of the biopsy specimen from the kidney, 7 glomeruli were present, of which 1 was obsolete and others showed mesangial widening and endocapillary proliferation with neutrophilic infiltration, subendothelial hyaline deposits (wire loops), and intraluminal thrombi in some of them. Half of the glomeruli revealed cellular crescents (Figures 1 and 2). There was no spike formation. Activity index was 18/24 and chronicity index, 5/12. The fluorescent antibody technique study revealed a typically full-house pattern (Figure 3). About 40% of tubules were atrophic. Based on clinical presentation and laboratory and pathologic findings, diagnosis of diffuse proliferative lupus nephritis (class-IV-G, A/C) was established.



**Figure 1.** Diffuse proliferative lupus nephritis (stage IV-G) with cellular crescent formation and interstitial infiltration.



**Figure 2.** Proliferative glomerulonephritis with wire loops and intraluminal thrombi (arrows).



**Figure 3.** Immunofluorescent antibody technique study revealed a typically full-house pattern.

## QUIZ

Which Immunosuppressive Do You Choose: Cyclophosphamide or Mycophenolate Mofetil?

The optimal treatment of lupus nephritis depends on the severity and type of renal involvement. In patients with proliferative lupus nephritis, immunosuppressive therapy consists of induction and maintenance phases. The optimal regimen and length of treatment for induction and maintenance therapy are controversial. Prolonged cyclophosphamide-corticosteroid therapy for both induction and maintenance phase is significantly beneficial in terms of induction of remission, episodes of relapse, preservation of kidney function, and prevention of kidney failure. However, these drugs may be associated with morbidity and adverse effects.

There is emerging evidence supporting the effectiveness and safety of mycophenolate mofetil in the treatment of lupus nephritis. Mycophenolate mofetil may be an alternative in those who cannot tolerate or refuse to take cyclophosphamide, and recently, its use is proposed as initial therapy in patients with diffuse proliferative lupus nephritis. In a meta-analysis of 5 randomized controlled trials that compared the mycophenolate mofetil with other immunosuppressive regimens for induction therapy (4 trials) and maintenance therapy (2 trials),<sup>1</sup> the risk of infection was significantly lower with mycophenolate mofetil than with cyclophosphamide for induction therapy. This analysis also showed the complete remission rate tended to be significantly higher in patients receiving mycophenolate mofetil. This study concluded that the mycophenolate mofetil is superior to cyclophosphamide for inducing complete remission, while the risk of relapse in maintenance therapy might not be significantly different between the patients receiving mycophenolate mofetil and those receiving azathioprine.

The efficacy of mycophenolate mofetil was confirmed by another randomized trial,<sup>2</sup> in which 42 patients with diffuse proliferative lupus nephritis received either oral cyclophosphamide and prednisolone for 6 months, followed by 6 months of azathioprine and prednisolone, or prednisolone and mycophenolate mofetil at a dosage of 2 g/d for 12 months. Complete remission was seen in 81% of the patients treated with mycophenolate mofetil, and 14% had a partial remission, as compared with 76% and 14%, respectively, in the patients treated with cyclophosphamide and prednisolone, followed by azathioprine and prednisolone. Another meta-analysis on patients with relatively preserved

nephritis in the mycophenolate mofetil group (mean baseline serum creatinine, 93.3  $\mu\text{mol/L}$  to 112.7  $\mu\text{mol/L}$ ) and the cyclophosphamide group (mean baseline serum creatinine, 94.0  $\mu\text{mol/L}$  to 113.1  $\mu\text{mol/L}$ ), showed that mycophenolate may be associated with a decreased risk of end-stage renal disease or death.<sup>3</sup> In a 6-month randomized trial, Ginzler and colleagues<sup>4</sup> compared mycophenolate mofetil at an initial dosage of 1 g/d, gradually increased to 3 g/d, with monthly intravenous cyclophosphamide, 0.5 g/m<sup>2</sup>, gradually increased to 1 g/m<sup>2</sup>. Of 140 patients with systemic lupus nephritis, 39 had membranous nephritis, 22 had focal proliferative nephritis, and 79 had diffuse proliferative nephritis. There were significantly more complete remissions in the mycophenolate mofetil group than in the cyclophosphamide group (22.5% and 5.8%, respectively). Partial remission was observed in 29.6% of the patients with mycophenolate mofetil and 24.6% of those with cyclophosphamide. However, the selected patients had preserved kidney function at presentation.

In summary, although the results of effectiveness of mycophenolate mofetil in the treatment of lupus nephritis are encouraging, evidence on its effectiveness in the treatment of severe lupus nephritis is mostly in those patients presented with preserved kidney function, which warrants a head-to-head study comparing the effectiveness of mycophenolate mofetil and cyclophosphamide in patients with severe kidney dysfunction.

## REFERENCES

1. Zhu B, Chen N, Lin Y, et al. Mycophenolate mofetil in induction and maintenance therapy of severe lupus nephritis: a meta-analysis of randomized controlled trials. *Nephrol Dial Transplant*. 2007;22:1933-42.
2. Chan TM, Li FK, Tang CS, et al. Efficacy of mycophenolate mofetil in patients with diffuse proliferative lupus nephritis. Hong Kong-Guangzhou Nephrology Study Group. *N Engl J Med*. 2000;343:1156-62.
3. Walsh M, James M, Jayne D, Tonelli M, Manns BJ, Hemmelgarn BR. Mycophenolate mofetil for induction therapy of lupus nephritis: a systematic review and meta-analysis. *Clin J Am Soc Nephrol*. 2007;2:968-75.
4. Ginzler EM, Dooley MA, Aranow C, et al. Mycophenolate mofetil or intravenous cyclophosphamide for lupus nephritis. *N Engl J Med*. 2005;353:2219-28.

Correspondence to:

Pedram Ahmadpoor, MD

Department of Internal Medicine, Shahid Labbafinejad Medical Center, 9th Boustan, Pasdaran, Tehran, Iran

Tel: +98 21 2258 0333

Fax: +98 21 2258 0333

E-mail: pedram.ahmadpoor@gmail.com