

Trimethoprim-sulfamethoxazole Induced Hyponatremia and Hyperkalemia, The Necessity of Electrolyte Follow-up in Every Patient

Farzin Khorvash,¹ Firouzeh Moeinzadeh,² Ali Saffaei,³
Atousa Hakamifard⁴

¹Nosocomial Infection
Research Center, Isfahan
University of Medical Sciences,
Isfahan, Iran

²Isfahan Kidney Diseases
Research Center, Isfahan
University of Medical Sciences,
Isfahan, Iran

³Clinical Pharmacy Resident,
Student Research Committee,
Department of Clinical
Pharmacy, School of Pharmacy,
Shahid Beheshti University of
Medical Sciences, Tehran, Iran

⁴Department of Infectious
Diseases, School of Medicine,
Isfahan University of Medical
Sciences, Isfahan, Iran

Trimethoprim-sulfamethoxazole (TMP/SMX) is a bactericidal antibiotic. The most common adverse effect of TMP/SMX is skin rashes and gastrointestinal symptoms. Although hyperkalemia can occur with TMP/SMX component but hyponatremia is uncommon. A 55-year old woman, known case of rheumatoid arthritis, presented with fever and mild dyspnea. According to diagnostic work up the infection with pneumocystis jirovecii was confirmed. TMP/SMX was started but after 10 days the patient acutely represented with nausea and became lethargic. The laboratory studies showed moderate hyperkalemia and severe hyponatremia. TMP/SMX was stopped and alternative treatment started. Upon discontinuation of the drug, serum sodium and potassium levels were both changed to normal. Hyponatremia as a life threatening adverse effect appears to be rare with TMP-SMX therapy, but clinicians should be aware of electrolyte disturbances developed with this drug and electrolyte monitoring should always be considered.

Keywords.

IJKD 2019;13:277-80
www.ijkd.org

INTRODUCTION

Trimethoprim-sulfamethoxazole (TMP/SMX) is a synthetic sulfonamide antibacterial combination.¹ This agent is effective against gram-negative and gram-positive bacteria, *P. jirovecii*; and also some protozoa.² The most common adverse reactions are skin rashes, nausea, vomiting, and diarrhea. Life-threatening adverse effects such as toxic epidermal necrolysis, Stevens–Johnson syndrome, and aplastic anemia may also occur.³ Additionally electrolyte disturbances may appear which hyperkalemia is the most common. Hyponatremia has also been reported.⁴ Simultaneous presentation of these two disturbances is an unusual condition. Here, we describe a case with the diagnosis of pneumocystis pneumonia, manifested with hyperkalemia, and severe hyponatremia while receiving high dose of TMP/SMX.

CASE REPORT

A 55-year old woman, known case of rheumatoid arthritis, presented with fever and mild dyspnea. Recently, she had been treated with prednisone 60 mg/d for 3 months and on admission the patient was treated with prednisone 30 mg/d from one month ago. She also received hydroxychloroquine and folic acid once daily. Cell blood count showed White blood cell count (WBC) = 5600, Hemoglobin (Hb) = 9.1, platelet (PLT) = 145000, Sodium (Na) = 146 mEq/L, potassium (K) = 4.2 mEq/L, BUN = 24, and Creatinine (Cr) = 1. Serum erythrocyte sedimentation rate (ESR) and C-reactive protein (CRP) were 55 mm/h and 72 mg/dL, respectively. Other laboratory results were within normal ranges including renal, liver and thyroid function tests. In thorax computed tomography (CT) scan diffuse bilateral ground glass opacity

was seen. Considering these findings an empiric antimicrobial regimen including levofloxacin, vancomycin, and cotrimoxazole were started. Also dose of prednisolone was increased to 50 mg/d. The diagnosis of pneumocystis pneumonia was established by bronchoscopy and bronchoalveolar lavage (BAL). Hence the intravenous TMP-SMX (15 mg/kg based on TMP dose, the patient weight was 70 kg) was continued and levofloxacin and vancomycin both were stopped. Furthermore prednisone 50 mg was continued. At the 10th day the patient acutely presented with nausea, vomiting and became confused and lethargic. The results revealed that serum sodium and potassium levels were 110 mEq/L and 6 mEq/L, respectively. The patient developed severe hyponatremia and moderate hyperkalemia that were noticeable. Prednisolone stopped and hydrocortisone 50 mg every 8 hour was started. Because the patient was ill and had severe hyponatremia and moderate hyperkalemia, suspicious drug (TMP/SMX) discontinued and alternative regimen with primaquine and clindamycin was started and management of hyponatremia and hyperkalemia performed simultaneously.

After rapid infusion of NaCl 3% (1.5 meq/L/h for 3h) neurologic symptoms have abated gradually and serum sodium increased to 120 meq/L in first 24 hours. According to low plasma osmolality (240 mosmol/kg) and high urine sodium level (50 meq/L), it seemed a true hyponatremia with impaired water excretion occurred. Cr level was 0.9 and the patient GFR was 78 cc/min/1.73 m². She had no consumption of thiazide diuretics with no edema or ascites. The patient had no hypotension. Thyroid function tests and serum cortisol levels were normal. Uric acid level was 5.2 mg/dL. Plasma renin was 25 pg/mL (normal range: 12 - 36 pg/mL), and plasma aldosterone was 76 pg/mL (normal range: 30 - 400 pg/mL). SIADH was ruled out. Upon discontinuation of the drug, serum sodium level increased to 131 mEq/L during next 48-hour without any other intervention. Her ECG recording did not show any hyperkalemic effect. We used insulin and glucose for shifting potassium into cells (10 units of regular insulin with 50 g of glucose to prevent hypoglycemia) and potassium level did not increase more. Following the drug discontinuation, serum potassium level decreased to 4.5 mEq/L and symptoms of electrolyte

disturbances disappeared.

DISCUSSION

We present a unique case of severe hyponatremia and moderate hyperkalemia while receiving high dose TMP/SMX for treatment of pneumocystis pneumonia. Severe hyponatremia (Serum Na level < 125 mEq/L) can cause cerebral edema, seizure, confusion, decreased consciousness, and death.⁵ Hyperkalemia can lead to arrhythmia and muscle paralysis. There are two probable mechanisms for TMP induced hyperkalemia. First TMP acts as potassium sparing diuretic, which blocks amiloride-sensitive sodium channels in collecting ducts.⁶ The chemical structures of TMP and amiloride have high similarity (Figure), hence TMP can mimic the amiloride effects and induces hyperkalemia. Second, TMP inhibits renal potassium secretion in a dose dependent manner.⁷ This drug especially at high doses can cause renal salt wasting and hyponatremia.⁸

There are some cases in literature which reported hyponatremia or hyperkalemia by TMP/SMX that summarized in Table.

Electrolyte disturbance due to cotrimoxazole usage usually has been shown in patients who receive drugs that can impair electrolyte balances such as diuretics,⁹ Angiotensin converting enzyme inhibitors^{10,11,12,13} and Angiotensin II receptor blockers¹⁴ as well as in patients with impaired renal function. Noto H et al. reported both hyperkalemia and hyponatremia with high doses of cotrimoxazole in two patients (Hodgkin disease and acute myeloblastic leukemia) without any risk factor for electrolyte disturbances similar to our case.¹⁵ Also other few cases have been reported.^{16,17}

Many reported cases have risk factors for electrolyte disturbances such as renal failure or usage of ACEIs, ARBs or diuretics, which are described in Table. Therefore in these cases the effect of TMP-SMX is difficult to interpret. In

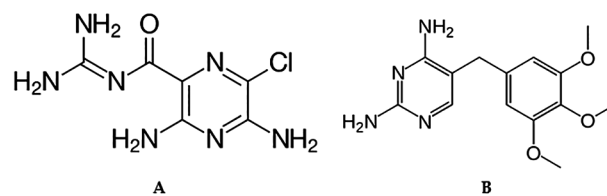


Figure. It shows the similar chemical structure of Amiloride (A) and TMP (B).

Table. Previous Cases of Electrolyte Disturbance Following TMP/SMX Administration

Authors	Year	Sex	Age	Dose	Electrolyte Disturbances Type		Risk Factor for Electrolyte Disturbances
					Hyponatremia	Hyperkalemia	
Our Case	2018	Female	55	High Dose	*	*	None
Huntsberry AM and et al.	2015	Female	82	Standard	*		ACE Usage
Lee SW and et al.	2014	Female	76	Standard		*	ARB Usage
Nickels LC and et al.	2012	Female	61	Standard		*	ACE Usage
Dunn RL and et al.	2011	Male	86	Standard	*		Diuretic Usage
Margassery S and et al.	2001	Male	77	Standard		*	ACE Usage
Koç M and et al.	2000	Male	31	Standard	*	*	Renal Transplantation
		Male	28	Standard	*	*	Renal Transplantation
Marinella MA and et al.	1997	Male	81	Standard		*	ACE Usage
Esther P and et al.	1996	Female	96	Standard		*	Several Underlying Disease
Mihm LB and et al.	1995	Male	25	High Dose		*	None
Noto H and et al.	1995	Male	64	High Dose	*	*	None
		Male	59	High Dose	*	*	None

contrast, our patient developed severe hyponatremia and moderate hyperkalemia following high dose of TMP/SMX in the absence of any risk factor including adrenal insufficiency, other drug usage and renal failure, which interacts with electrolyte balances. Accordingly we can conclude that high dose of cotrimuxazole can effect directly on renal distal tubules and then inhibits potassium excretion and sodium reabsorption, ultimately induces hyperkalemia and hyponatremia. According to severe hyponatremia and critical condition we discontinued the only suspicious drug and started alternative regimen. This case emphasize that clinicians must be aware of electrolyte disturbances, which developed, by TMP/SMX and electrolyte monitoring should always be considered during therapy. This recommendation ought to be done for all patients including those with no risk factor for electrolyte disturbances.

REFERENCES

- Ho JMW and Juurlink DN. Considerations when prescribing trimethoprim-sulfamethoxazole. *CMAJ* : Canadian Medical Association journal = journal de l'Association medicale canadienne 2011; 183:1851-8.
- Castro JG and Morrison-Bryant M. Management of Pneumocystis Jirovecii pneumonia in HIV infected patients: current options, challenges and future directions. *HIV/AIDS (Auckland, N.Z.)* 2010; 2:123-34.
- Goldman JL, Jackson MA, Herigon JC, Hersh AL, Shapiro DJ and Leeder JS. Trends in adverse reactions to trimethoprim-sulfamethoxazole. *Pediatrics* 2013; 131:e103-e8.
- Mori H, Kuroda Y, Imamura S, et al. Hyponatremia and/or hyperkalemia in patients treated with the standard dose of trimethoprim-sulfamethoxazole. *Intern Med* 2003; 42:665-9.
- Chaudhari AP, Pavan M and Mehta HJ. Influence of Fluid Balance on Morbidity and Mortality in Critically Ill Patients With Acute Kidney Injury. *Iran J Kidney Dis* 2016; 10:177-81.
- Pimenta E. Update on diagnosis and treatment of resistant hypertension. *Iran J Kidney Dis* 2011; 5:215-27.
- Velazquez H, Perazella MA, Wright FS, Ellison DH. Renal mechanism of trimethoprim-induced hyperkalemia. *Annals of internal medicine*. 1993 Aug 15;119(4):296-301.
- Kaufman AM, Hellman G, Abramson RG. Renal salt wasting and metabolic acidosis with trimethoprim-sulfamethoxazole therapy. *The Mount Sinai journal of medicine, New York*. 1983;50(3):238-9.
- Dunn RL, Smith WJ and Stratton MA. Trimethoprim-sulfamethoxazole-induced hyponatremia. *Consult Pharm* 2011; 26:342-9.
- Huntsberry AM, Linnebur SA and Vejar M. Hyponatremia after initiation and rechallenge with trimethoprim-sulfamethoxazole in an older adult. *Clinical Interventions in Aging* 2015; 10:1091-6.
- Nickels LC, Jones C and Stead LG. Trimethoprim-Sulfamethoxazole-Induced Hyperkalemia in a Patient with Normal Renal Function. *Case Reports in Emergency Medicine* 2012; 2012:815907.
- Margassery S and Bastani B. Life threatening hyperkalemia and acidosis secondary to trimethoprim-sulfamethoxazole treatment. *J Nephrol* 2001; 14:410-4.
- Marinella MA. Trimethoprim-sulfamethoxazole associated with hyperkalemia. *West J Med* 1997; 167:356-8.
- Lee SW, Park SW and Kang JM. Intraoperative hyperkalemia induced by administration of trimethoprim-sulfamethoxazole in a patient receiving angiotensin receptor blockers. *J Clin Anesth* 2014; 26:427-8.
- NOTO H, KANEKO Y, TAKANO T, KUROKAWA K. Severe hyponatremia and hyperkalemia induced by trimethoprim-sulfamethoxazole in patients with Pneumocystis carinii pneumonia. *Internal medicine*. 1995;34(2):96-9.
- Mihm LB, Rathbun RC and Resman-Targoff BH. Hyperkalemia associated with high-dose trimethoprim-

sulfamethoxazole in a patient with the acquired immunodeficiency syndrome. *Pharmacotherapy* 1995; 15:793-7.

17. Koc M, Bihorac A, Ozener CI, Kantarci G and Akoglu E. Severe hyperkalemia in two renal transplant recipients treated with standard dose of trimethoprim-sulfamethoxazole. *Am J Kidney Dis* 2000; 36:E18.
18. Perlmutter EP, Sweeney D, Herskovits G and Kleiner M. Case report: severe hyperkalemia in a geriatric patient receiving standard doses of trimethoprim-sulfamethoxazole. *Am J Med Sci* 1996; 311:84-5.

Correspondence to:
Atousa Hakamifard, MD
Department of Infectious Diseases, School of Medicine, Isfahan
University of Medical Sciences, Isfahan, Iran
Email: a.hakamifard@med.mui.ac.ir

Received November 2018

Revised March 2019

Accepted June 2019